

Spinal Capillary and Cavernous Haemangiomas in Developmental Age: Our Experience

Anthony Kevin Scafa¹, Giorgio Santoro^{1*}, Vito Chiarella¹, Nicoletta Greco², Massimo Corsini¹, Manolo Piccirilli¹

¹Department of Human Neurosciences, Neurosurgery, Sapienza University, 00185 Rome, Italy

²Department of Translational and Precision Medicine, Sapienza University, 00185 Rome, Italy

*Correspondence should be addressed to Giorgio Santoro; giorgio8480@gmail.com

Received date: October 01, 2021, **Accepted date:** October 19, 2021

Copyright: © 2021 Scafa AK, et al. This is an open-access article distributed under the terms of the Creative Commons Attribution License, which permits unrestricted use, distribution, and reproduction in any medium, provided the original author and source are credited.

Vascular anomalies are quite common lesions. They are frequently encountered in the pediatric population, being present at birth or developing later, during infancy, childhood, or adolescence. Most of these lesions are benign. Nevertheless, even benign lesions may exhibit significant morbidity without idoneous management [1].

In 1863, Virchow proposed the first classification of vascular anomalies. He considered these lesions to be *tumors* ("angiomas") and classified them into three categories ("simplex", "cavernosum", and "racemosum") according to the microscopic appearance of the diseased vascular channels [2]. It was subsequently stated that angiomas could be either capillary, venous or arterial (with or without fistulae) based on the stage at which vascular morphogenesis was altered [3]. Setting aside Virchow's hypothesis, Mulliken and Glowacki, in 1982, developed a new, "binary" classification model in which they distinguished *true* (1) vascular "hemangiomas", characterized by cellular hyperplasia, from (2) vascular "malformations" which instead demonstrated vessel dysplasia with *normal* rates of cellular turnover. They also described the different biological behavior of the two "entities" in terms of tendency to spontaneous regression (present in vascular hemangiomas, absent in vascular malformations) [4]. This scheme was later embraced by the "International Society for the Study of Vascular Anomalies" (ISSVA) at the 1996 meeting in Rome [5], "expanded" at the 2014 ISSVA workshop in Melbourne, and last revised in 2018 (the updates were crucial to fully incorporate the genetic and histopathological advances in the knowledge of these lesions) [6,7]. Vascular tumors were divided into *benign*, *borderline/locally aggressive*, and *malignant*, and were also further sub-classified by pattern and location to include syndromic associations, such as PHACE (*posterior fossa brain malformations, large facial hemangiomas,*

anatomical anomalies of the cerebral arteries, aortic coarctation and other cardiac anomalies, eye abnormalities) and LUMBAR (*lower body congenital infantile hemangiomas and other skin defects, urogenital anomalies and ulceration, myelopathy, bony deformities, anorectal malformations and arterial anomalies, rectal anomalies*) [7].

In their 1993 paper, Coffin and Dehner reviewed 228 vascular tumors found in 222 children and adolescents. Of these tumors, 89% were benign, 9% were borderline or indeterminate, and 2% were malignant. The mean age at diagnosis was 12 years; 26% of cases were diagnosed in the first year of life and 57% within the first decade. M:F ratio was 1:2. "Capillary hemangioma" was the most common type (32%) [8].

Capillary hemangiomas (CHs) are the most frequent tumor of infancy affecting 10% of Caucasian children [9]. They are benign vascular tumors frequently found in the skin (face, neck, back) and in nasal or oral mucosa. They usually develop at birth or in early infancy, go through a proliferative phase which is followed by a stable period, and then generally (but not always) involute over months or years, even if not treated [10].

Central nervous system (CNS) involvement is uncommon and may occur in a wider range of age [11]. In our 2020 paper, we extensively reviewed the available literature, identifying 41 publications for a total of 52 cases with histopathological diagnosis of intracranial CH; we also described one case from our personal experience (a rare case of Meckel cave's capillary hemangioma presenting with trigeminal neuralgia in a 36-year-old man). The mean age of these patients was 26 years (range 0–80), and females were slightly more frequently affected (28 F vs 25 M) [12].

Within the spine, CHs are not uncommon. They are usually located in the thoracolumbar spine, frequently involving vertebral bodies [13]. Lesions affecting spinal cord and nerves are less frequent. They normally reside in the intradural extramedullary space or in the intramedullary compartment, while extradural location is uncommon [14,15]. They are usually an incidental finding on radiological images; only a minority of these lesions is associated with symptoms [16]. On MRI they appear isointense (relative to the spinal cord) on T1WI, and hyperintense on T2WI. They also show a peculiar, "strong" homogeneous contrast enhancement. Large-sized lesions can determine a mass effect on the spinal cord, and this can be demonstrated as a high T2 signal [17]. Differential diagnosis includes meningiomas, schwannomas, and hemangioblastomas. Among these, only CHs show (1) "avid" enhancement and (2) hyperintensity on T2WI [18].

As for intracranial CHs, clinical debut of spinal CHs is typically seen in late adolescence or in adulthood, even though these lesions normally develop earlier. Spontaneous involution may be, for this location, less probable. Symptoms may include back pain, lower limb paresthesia's, weakness, and/or sphincter disturbances [16].

We recently admitted to our ward a 23-year-old female

student with negative past medical history, who arrived at the emergency department of our Institute complaining intense sacral pain, resistant to analgesics and progressively worsened in the last month. The CT scan of the lumbosacral spine showed a 53 × 45 × 39 mm isodense mass in the left hemi-sacrum with osteodestructive phenomena causing interruption of the cortical bone in the antero-inferior portion of the sacrum itself, and with extension to the ipsilateral sacroiliac joint without interruption of the bone cortex at that level (Figure 1). The MRI confirmed the presence of the mass which also showed signs of extraosseous extension within the left pre-sacral space of the pelvic cavity and inside the left S1-S2 neuroforamina. The lesion was isointense (relative to pelvic visceral contents) on T1WI, and hyperintense on T2WI; it also showed marked enhancement after gadolinium injection (Figure 2). The tumor, thought to be an aggressive sacral sarcoma, was partially embolized and then biopsied. Upon histopathological examination, it appeared as a collection of lobules containing clusters of thin-walled capillaries separated by thin reticular septa. Final diagnosis was that of "capillary hemangioma". The patient was then offered two treatment options, i.e., complete Onyx® embolization and radiotherapy. In relation to the potential risk of infertility due to the proximity of the ovaries, radiotherapy was, though, excluded.

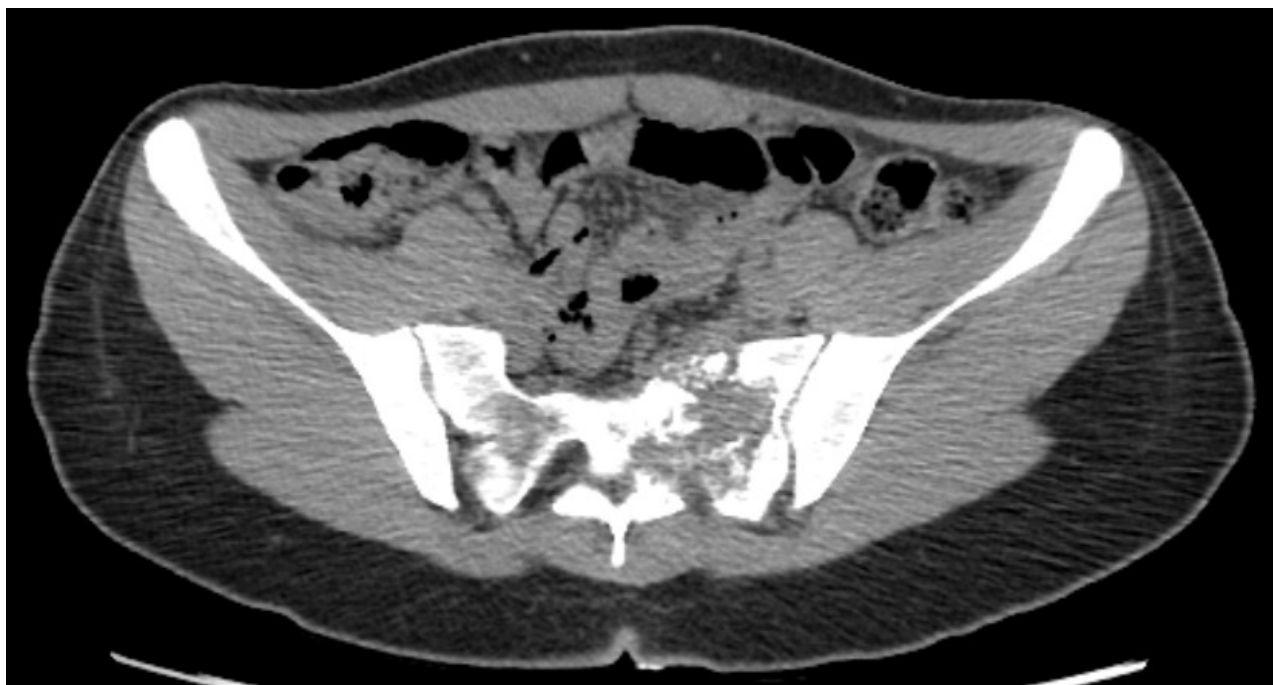

Figure 1: Case 1. Sacral capillary hemangioma. Preoperative CT scan. Note the presence of an isodense mass in the left hemi-sacrum with osteodestructive with extension to the ipsilateral sacroiliac joint without interruption of the bone cortex at the level.

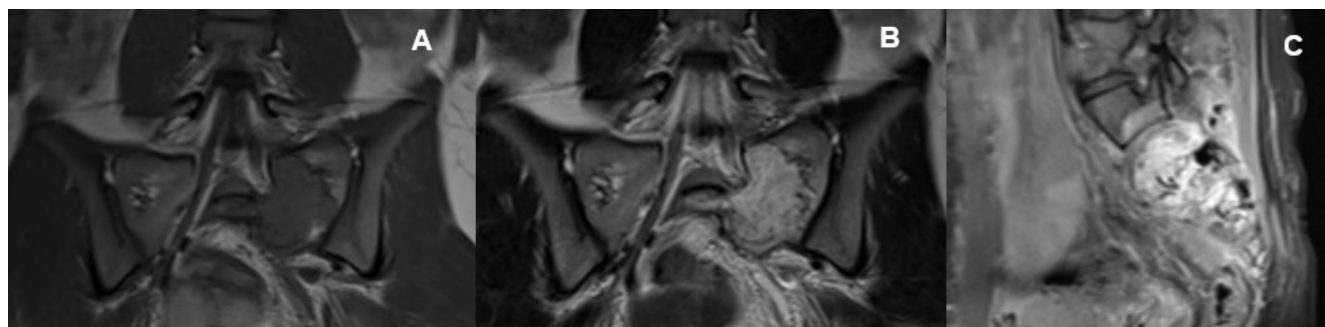

Figure 2: Case 1. Sacral capillary hemangioma. Preoperative MRI. **(A)** Coronal section, T1WI showing a non-enhanced isointense mass within the left sacrum. **(B)** Coronal section, T2WI showing hyperintensity of the lesion. **(C)** Sagittal section, T1WI C+. Note the avid enhancement of the lesion.

According to some authors, it is possible for CHs to progress to cavernous hemangiomas [8,19] which, unlike childhood CHs, do not present any type of involution [19].

This may be particularly true for spinal CHs, whose natural history is only poorly understood.

In contrast to CHs, cavernous hemangiomas – more properly “malformations” rather than tumors – exhibit much larger lumens, together with wider and more severely collagenized trabeculae. Most of CNS cavernous malformations (CMs) occurs in the brain, with 63%-90% in the supratentorial compartment [20]. Spinal CMs are rare, accounting for

3-16% of all spinal vascular anomalies. Like CHs, they usually originate from the vertebral body, but other locations (i.e., intramedullary, intradural-extramedullary, or extradural) are described [21]. Though fundamentally *congenital*, similarly to CHs, CMs are usually discovered in adulthood, probably for a greater “compliance” and a lower incidence of acute bleeding presentation in children [22]. Not long ago, however, an 8-year-old female Bangladeshi child affected by a cervicothoracic hemorrhagic spinal extradural CM (Figure 3) was treated at our Institution. A C7–T2 laminectomy with excision of the lesion was performed with good recovery in terms of motor and sphincter functions (Figure 4).

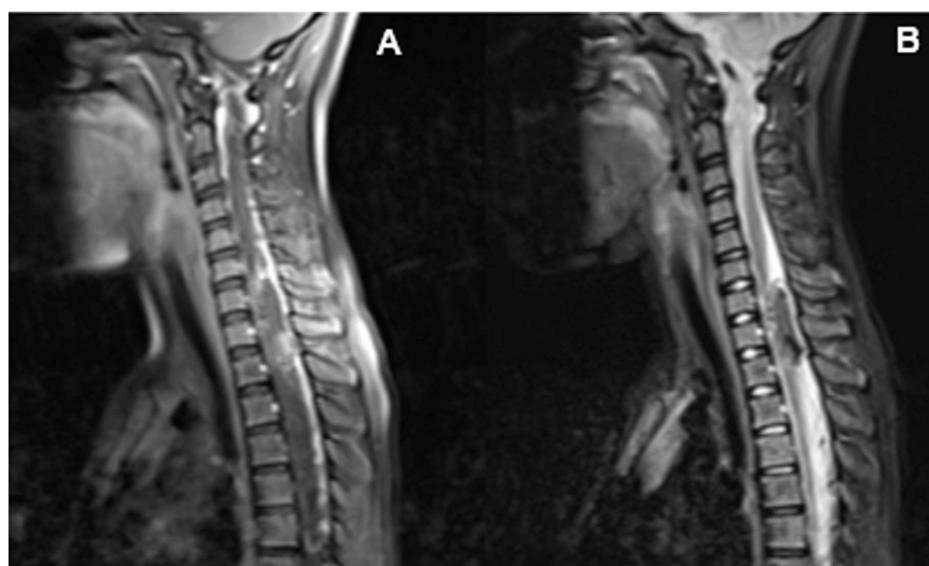


Figure 3: Case 2. Cervical hemorrhagic extradural cavernous hemangioma. Preoperative MRI. **(A)** Sagittal section, C+ T1WI showing a non-enhanced iso-hyperintense epidural mass compressing the thecal sac from behind. Note the edema of the paravertebral soft tissues and the straightening of the cervical spine from antalgic contracture. **(B)** Sagittal section, T2WI showing hypointense signal of the lesion.

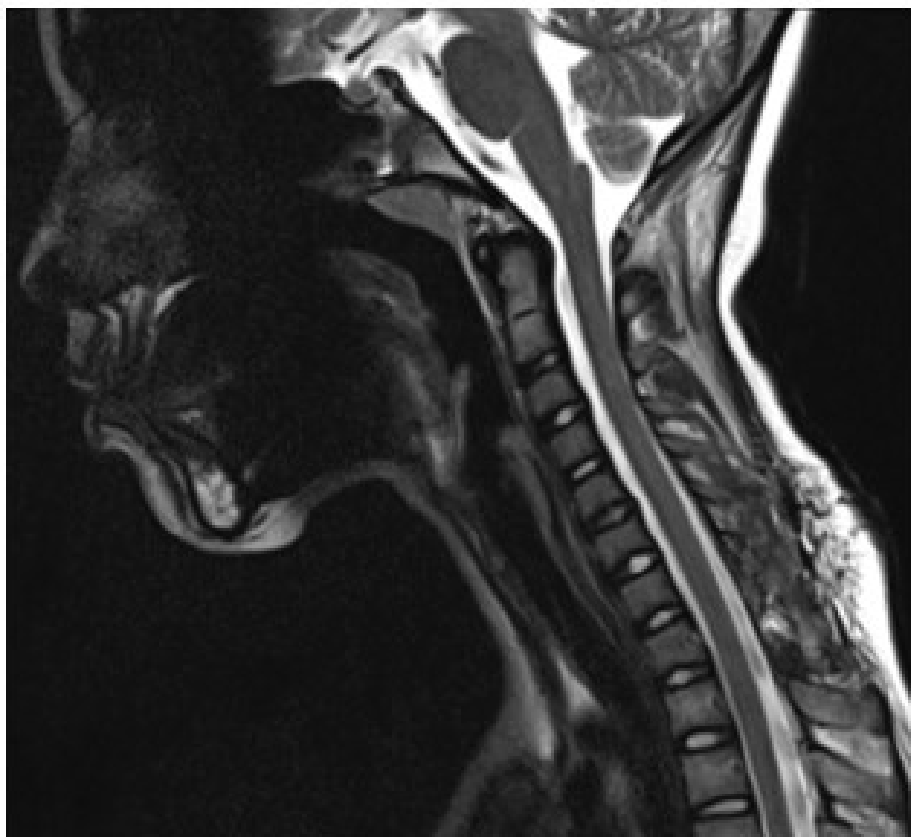


Figure 4: Case 2. Cervical hemorrhagic extradural cavernous hemangioma. Postoperative MRI. Sagittal section, T2WI showing no further bleedings and a realigned medullary cord. Partial restoration in cervical lordosis.

To conclude, vascular tumors are relatively common, especially in early ages. However, given the frequent delayed diagnosis, often related to a subacute or acute presentation in adulthood, it could be useful to screen newborns for germline mutations in potentially predisposing genetic pathways. As for CMs [23], three (different) candidate genes involved with angiogenesis have been studied in children affected by CHs: (1) *fibroblast growth factor receptor-4* (FGFR4), (2) *platelet-derived growth factor receptor-beta* (PDGFRB), and (3) *fms-related tyrosine kinase-4* (FLT4). These genes and their products, typically associated with familial hemangiomas, may be involved in the more common sporadic cases [24]. This should lead to further investigation with the purpose of an earlier diagnosis. Observation is the rule for asymptomatic spinal hemangiomas. When severe pain or neurological deficits occur, treatment is necessary. There are many options that must be weighed. Open surgery, radiotherapy, balloon kyphoplasty, and trans arterial embolization are some of those options [25].

Conflict of Interest

The authors have no conflicts of interest to declare.

Ethical Approval

All procedures performed in this study were in accordance with the ethical standards of the institutional and/or national research committee and with the 1964 Helsinki declaration and its later amendments or comparable ethical standards.

Data Availability Statement

All data generated or analyzed during this study are included in this article. Further enquiries can be directed to the corresponding author.

References

1. Hinen HB, Trenor III CC, Lee LW. Childhood Vascular Tumors. *Frontiers in Pediatrics.* 2020;8.
2. Virchow R. *Angiome. Die Krankhaften Geschwülste.* Berlin: August Hirschwald, 1863. Vol. 3, p. 306
3. Malan E, Tradito E, editors. *Vascular Malformations: (angiodyplasias).* Carlo Erba Foundation; 1974.
4. Mulliken JB, Glowacki J. *Hemangiomas and vascular*

malformations in infants and children: a classification based on endothelial characteristics. *Plastic and Reconstructive Surgery*. 1982 Mar 1;69(3):412-22.

5. Enjolras O. Classification and management of the various superficial vascular anomalies: hemangiomas and vascular malformations. *The Journal of Dermatology*. 1997 Nov;24(11):701-10.

6. ISSVA Classification of Vascular Anomalies © 2014. International Society for the Study of Vascular Anomalies Available at: issva.org/classification.

7. Blei F. Nomenclature of Vascular Anomalies: Evolution to the ISSVA 2018 Classification System. In *Vascular Anomalies 2020* (pp. 1-8). Springer, Cham.

8. Coffin CM, Dehner LP. Vascular tumors in children and adolescents: a clinicopathologic study of 228 tumors in 222 patients. *Pathology Annual*. 1993 Jan 1;28: 97-120.

9. Davies BW, Pierce KK, Holck DE. Capillary hemangioma treatment. *Ophthalmology*. 2012 Sep 1;119(9):1938: e1-1938.e19382.

10. Gold R, O'Keefe M, Langer P. Management of capillary hemangiomas. *Journal of Pediatric Ophthalmology & Strabismus*. 2006;43(6):326-330.

11. Abe M, Tabuchi K, Tanaka S, Hodozuka A, Kunishio K, Kubo N, et al. Capillary hemangioma of the central nervous system. *Journal of Neurosurgery*. 2004 Jul 1;101(1):73-81.

12. Santoro G, Piccirilli M, Chiarella V, Greco N, Berra LV, Santoro A. Intracranial capillary hemangiomas: literature review in pediatric and adult population. *Neurosurgical Review*. 2020 Oct 20:1-9.

13. Ciftdemir M, Kaya M, Selcuk E, Yalniz E. Tumors of the spine. *World Journal of Orthopedics*. 2016 Feb 18;7(2):109-112.

14. Rajpal S, Johs S, Zaronias C, Forsythe RC, Burneikiene S. Spinal Epidural Capillary Hemangioma with Intrathoracic Extension: Case Report and Review of the Literature. *Cureus*. 2020 Jul;12(7).

15. Xu H, Tong M, Liu J, Zhou G, Chen F. Purely spinal epidural capillary hemangiomas. *Journal of Craniofacial Surgery*. 2018 May 1;29(3):769-71.

16. Abe M, Tabuchi K, Tanaka S, Hodozuka A, Kunishio K, Kubo N, Nishimura Y. Capillary hemangioma of the central nervous system. *Journal of Neurosurgery*. 2004 Jul 1;101(1):73-81.

17. Gupta S, Kumar S, Banerji D, Pandey R, Gujral R. Magnetic resonance imaging features of an epidural spinal haemangioma. *Australasian Radiology*. 1996 Aug;40(3):342-4.

18. Puac P, Jansen G, Zakhari N. Capillary Hemangioma: An Important Consideration in the Repertoire of Spinal Tumors. *Canadian Journal of Neurological Sciences*. 2021 Jul;48(4):562-4.

19. Tsao MN, Schwartz ML, Bernstein M, Halliday WC, Lightstone AW, Hamilton MG, et al. Capillary hemangioma of the cavernous sinus: report of two cases. *Journal of Neurosurgery*. 2003 Jan 1;98(1):169-74.

20. Giombini S, Morello G. Cavernous angiomas of the brain. *Acta Neurochirurgica*. 1978 Mar;40(1):61-82.

21. Santoro A, Piccirilli M, Bristot R, Di Norcia V, Salvati M, Delfini R. Extradural spinal cavernous angiomas: report of seven cases. *Neurosurgical Review*. 2005 Oct;28(4):313-9.

22. Sarikaya-Seiwert S, Gierga K, Wessalowski R, Steiger HJ, Hänggi D. Solitary spinal epidural cavernous angiomas in children presenting with acute neurological symptoms caused by hemorrhage: report of 2 cases. *Journal of Neurosurgery: Pediatrics*. 2010 Jan 1;5(1):89-93.

23. Akers A, Al-Shahi Salman R, A. Awad I, Dahlem K, Flemming K, Hart B, et al. Synopsis of guidelines for the clinical management of cerebral cavernous malformations: consensus recommendations based on systematic literature review by the angioma alliance scientific advisory board clinical expert's panel. *Neurosurgery*. 2017 May 1;80(5):665-80.

24. Walter JW, Blei F, Anderson JL, Orlow SJ, Speer MC, Marchuk DA. Genetic mapping of a novel familial form of infantile hemangioma. *American Journal of Medical Genetics*. 1999 Jan 1;82(1):77-83.

25. Fox MW, Onofrio BM. The natural history and management of symptomatic and asymptomatic vertebral hemangiomas. *Journal of Neurosurgery*. 1993 Jan 1;78(1):36-45.