

# Coronary Revascularization in the Era of Transcatheter Aortic Valve Replacement: Treat the Patient, Manage the Disease

Pradyumna E Tummala\*, Cindy L Grines

Northside Hospital Cardiovascular Institute, Atlanta GA, United States

\*Correspondence should be addressed to Pradyumna E Tummala; Prad.Tummala@northside.com, petummala@yahoo.com

**Received date:** April 14, 2021, **Accepted date:** November 08, 2021

**Copyright:** © 2021 Tummala PE, et al. This is an open-access article distributed under the terms of the Creative Commons Attribution License, which permits unrestricted use, distribution, and reproduction in any medium, provided the original author and source are credited.

**Keywords:** Aortic stenosis, Cardiac catheterization, Coronary angiography, Coronary revascularization, Percutaneous coronary intervention (PCI), Transcatheter aortic valve replacement (TAVR)

Coronary artery disease continues to be the greatest cause of global mortality. The prevalence of coronary artery disease in patients with severe aortic stenosis varies widely, from 80% in extreme high-risk trials to only 15% in more recent low risk trials [1-3]. Given the higher risk of mortality in patients with coronary artery disease, guidelines suggest that revascularization with coronary artery bypass grafting (CABG) be considered in patients undergoing surgical aortic valve replacement [4]. Therefore, early trials of transcatheter aortic valve replacement (TAVR) required coronary angiography prior to consideration of TAVR. Percutaneous coronary intervention (PCI) of proximal and mid lesions in major coronary arteries was recommended during the first decade of TAVR. Yet there have been conflicting data with regard to outcomes of patients undergoing PCI prior to TAVR.

Faroux et al. reported a series of 1197 patients (1705 lesions) with mean age 81 treated with PCI during the TAVR workup. Of these, 94% of PCI's were performed prior to TAVR, at a median of 41 days, and 5.6% were performed at the time of TAVR [5]. Half of the patients had multi-vessel disease and lesion morphology was often complex; 50% of the lesions were calcified and 46% involved bifurcations. Despite advanced age of 81 and complexity of disease, PCI success was achieved in 97%. At a median 2-year follow-up, target vessel failure occurred in only 3.3% and was predicted by baseline co-morbidities and incomplete revascularization. Higher than expected use of bare metal stents suggests operators did not want to

use prolonged dual anti-platelet therapy (DAPT) and may have stopped DAPT prior to TAVR in the early experience, given higher rate of vascular and bleeding complications. Or perhaps the fact that patients were enrolled starting in 2007 reflects the drug eluting stents (DES) thrombosis scare that occurred at the time this registry began. Importantly, stent thrombosis occurred in only 5 patients (0.4%) at a median of 48 days post-TAVR and clinically apparent restenosis rate was infrequent at 2.3%. However, overall major adverse cardiac and cerebrovascular events (MACCE) occurred in about one third of patients, with acute coronary syndrome in 8.4%, death in 28.7% (cardiac death in 8.8%) likely reflecting age and comorbidities. Although the authors state, "these findings provide further reassuring information regarding the early safety of pre-TAVR PCI", there were no data provided regarding rates of death, myocardial infarction (MI) or CABG after PCI. We assume these patients may not have made it into the TAVR registry, so this is a potential limitation of the registry. Despite this, the high success rates and low complication rates in high-risk patients are encouraging.

Kotronias et al. performed a meta-analysis of nine studies involving 3858 patients who underwent TAVR, and of whom 983 (25%) underwent PCI [6]. Those who received PCI had a higher rate of major vascular complications (odds ratio [OR]: 1.86; 95% confidence interval [CI], 1.33-2.60;  $P=0.0003$ ) and higher 30-day mortality (OR: 1.42; 95% CI, 1.08-1.87;  $P=0.01$ ). There were no differences in 30-day cardiovascular mortality (OR: 1.03; 95% CI, 0.35-2.99), myocardial infarction (OR: 0.86; 95% CI, 0.14-5.28), acute kidney injury (OR: 0.89; 95% CI, 0.42-1.88), stroke (OR: 1.07; 95% CI, 0.38-2.97), or 1-year mortality (OR: 1.05; 95% CI, 0.71-1.56). There was also no difference in outcomes whether PCI was performed prior to TAVR or in the same setting of TAVR. In 14 studies that reported both

age and gender, the mean age was 85.3 years and 48.4% were female. The definition of anatomically significant CAD was not consistent and included at least  $\geq 50\%$  diameter stenosis in 7 studies,  $>70\%$  stenosis in 5 studies, and  $>90\%$  stenosis in 1 study. The 4 studies defined significant left main disease as  $>50\%$  stenosis. None of the studies reported on the use of functional assessment to identify significance of CAD.

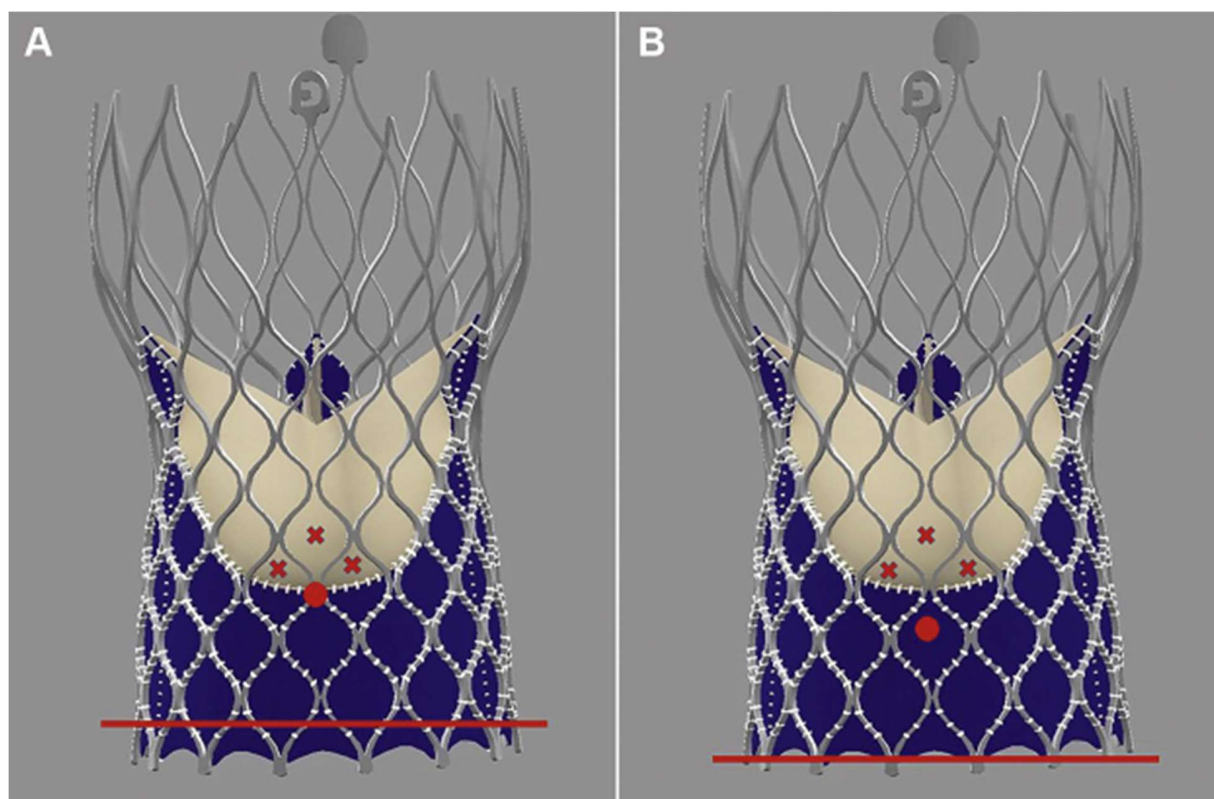
Kumar et al. reported outcomes on 3982 patients who underwent TAVR, 327 (8%) of whom underwent PCI within 1 year before TAVR, 3 (1%) had PCI on same day as TAVR, and 15 (0.5%) had PCI within 2 months of TAVR [7]. Patients who received PCI and TAVR had lower MACCE rates if they had previous CABG (HR 0.501), higher BMI (HR 0.970), and on statin therapy after TAVR (HR 0.660). Those on warfarin therapy after TAVR had a higher MACCE rate (1.779). Patients who received PCI before TAVR had similar angiographic and clinical characteristics as those who received PCI at time of TAVR or afterwards, and success and MACCE rates were similar among the groups. However, the study population of patients receiving PCI was small, and whether there is an advantage of performing PCI before, with, or after TAVR remains unknown.

Taken altogether, it appears that PCI prior to or in the same setting as TAVR can be successfully performed, albeit with the upfront risk of periprocedural complications that come with treating an elderly patient population with complex coronary lesions. Yet, the question remains: should it be routinely performed? The initial rationale for performing PCI prior to TAVR in these patients was to mitigate ischemia and cardiac collapse that may occur during rapid ventricular pacing, difficulty passing or deploying first generation TAVR valves, vascular injury and bleeding with large bore access. Initial studies only enrolled elderly high-risk patients, so it made sense to require angiography and revascularization. Moreover, it became readily apparent that cannulating coronary arteries through TAVR struts could make subsequent PCI challenging, particularly when using supra-annular valves or when a second valve is placed to treat aortic insufficiency [8]. Thus, revascularization pre-TAVR made sense. With improved clinical experience and improvement in devices and techniques, the risks of acute ischemia and hemodynamic collapse while performing TAVR are now minimal in most cases. Coronary protection techniques including stenting of ostial left main and right coronary arteries and BASILICA (bioprosthetic or native aortic scallop intentional laceration to prevent iatrogenic coronary artery obstruction during TAVR) have been utilized to prevent potentially catastrophic periprocedural complications in patients whose anatomy is at high risk for acute coronary obstruction with TAVR [9].

Whether percutaneous coronary intervention (PCI) prior

to TAVR offers clinical benefit in patients with CAD remains unclear. To date, there have been no randomized trials addressing this issue. A meta-analysis of 11 cohort studies enrolling 5,580 patients (mean age 82.4 years) found no difference in 30-day all-cause mortality (OR 1.30 [0.85 to 1.98]), stroke (OR 0.7 [0.36 to 1.45]), MI (OR 2.71 [0.55 to 12.23]), acute kidney injury (OR 0.7 [0.46 to 1.06]), as well as no difference in 1-year all-cause mortality (OR 1.19 [0.92 to 1.52]), in patients who underwent TAVR with and without PCI [10]. However, as seen in many observational registries, sicker patients may have been treated, so potential benefits may not be apparent. But since we are now performing TAVR in intermediate and low risk patients that may live for several decades, some have suggested that it is even more important to revascularize these patients prior to TAVR if coronary access is impeded by the transcatheter aortic valve. Yet, in addition to development of techniques to improve acute ischemic complications, clinical experience with performing coronary angiography and interventions has grown significantly over the past decade. Techniques to improve success of cannulating coronary ostia and interventions have been refined, including using guide catheters with smaller curves (e.g., engaging the left coronary artery with a JL3 or EBU 3 from radial approach or JL3.5/EBU 3.5 from a femoral approach), remote wiring and using guide extension catheters, and utilizing the appropriate cells within the transcatheter valve to access the coronary ostia [11] (Figure 1). Our current state of abilities to perform PCI after TAVR is challenging, but promising. However, it is imperative that all interventionalists learn these adaptations to coronary angiography and interventions as more patients who are living longer after TAVR develop clinically significant coronary artery disease. These techniques are particularly important to know when patients with prior TAVR present with acute coronary syndromes, STEMI and cardiogenic shock in order to provide timely and life-saving care.

Putting what we know into context: We know that patients with higher coronary artery disease burden have worse outcomes compared to those with minimal or no coronary artery disease, independent of the presence of aortic stenosis [12,13]. Those who have left main, multivessel, and proximal LAD disease benefit from revascularization, particularly in the presence of left ventricular dysfunction [14,15]. Also, the benefits of improved angina control and quality of life with early revascularization in patients with hemodynamically significant coronary artery stenoses has been consistently shown in several studies involving PCI in patients with stable ischemic heart disease (SIHD) [16,17]. Additionally, in patients with SIHD, revascularization with PCI is limited to those with functionally significant coronary artery disease [18,19]. In patients with aortic stenosis, because of the added complexity of afterload reduction after TAVR, it is not clear whether utilizing currently accepted values of invasive coronary



**Figure 1:** Red dot represents the location of the coronary ostium in relation to the valve frame, and the red line represents the annular plane. The red x's depict the closest diamonds that can be used to access the coronary ostium. An optimally positioned Evolut-R (Medtronic, Galway, Ireland) (A) would make coronary access potentially easier than one with a higher implant (B); Yudi et al. [11].

hemodynamics such as fractional flow reserve (FFR) will translate into similar outcomes after PCI [20], but some studies support the utility of invasive functional assessment in patients with aortic stenosis. Putting these data into the context of treating individual patients is the goal shared by all physicians. For example, treating a 70-year-old physically active patient with functionally significant proximal epicardial CAD with PCI would likely be more clinically impactful than treating a similar lesion in an 85-year-old sedentary patient with other causes of debility and with less periprocedural complications. In the end, the decision to revascularize a patient with severe aortic stenosis should be made after contemplating the details of coronary anatomic complexity and functional significance, individual patient characteristics, and shared decision-making guided by good clinical judgment. No randomized, controlled trial or registry can incorporate all these elements to apply to each individual case.

## References

1. Faroux L, Guimaraes L, Wintzer-Wehekind J, Junquera L, Ferreira-Neto AN, Del Val D, et al. Coronary artery disease and transcatheter aortic valve replacement: *JACC*

state-of-the-art review. *Journal of the American College of Cardiology.* 2019 Jul 23;74(3):362-72.

2. Popma JJ, Deeb GM, Yakubov SJ, Mumtaz M, Gada H, O'Hair D, et al. Transcatheter aortic-valve replacement with a self-expanding valve in low-risk patients. *New England Journal of Medicine.* 2019 May 2;380(18):1706-15.

3. Mack MJ, Leon MB, Thourani VH, Makkar R, Kodali SK, Russo M, et al. Transcatheter aortic-valve replacement with a balloon-expandable valve in low-risk patients. *New England Journal of Medicine.* 2019 May 2;380(18):1695-705.

4. Falk V, Baumgartner H, Bax JJ, De Bonis M, Hamm C, Holm PJ, et al. 2017 ESC/EACTS Guidelines for the management of valvular heart disease. *European Journal of Cardio-Thoracic Surgery.* 2017 Oct 1;52(4):616-64.

5. Faroux L, Campelo-Parada F, Munoz-Garcia E, Nombela-Franco L, Fischer Q, Donaint P, et al. Procedural characteristics and late outcomes of percutaneous coronary intervention in the workup pre-TAVR. *Cardiovascular Interventions.* 2020 Nov 23;13(22):2601-13.

6. Kotronias RA, Kwok CS, George S, Capodanno D, Ludman PF, Townend JN, et al. Transcatheter aortic valve implantation with or without percutaneous coronary artery revascularization strategy: a systematic review and meta-analysis. *Journal of the American Heart Association.* 2017 Jun 27;6(6):e005960.
7. Kumar A, Sammour Y, Reginauld S, Sato K, Agrawal N, Lee JM, et al. Adverse clinical outcomes in patients undergoing both PCI and TAVR: analysis from a pooled multi-center registry. *Catheterization and Cardiovascular Interventions.* 2021 Feb 15;97(3):529-39.
8. Latif F Mujlukutia S. Coronary angiography and interventional following TAVR: Challenges and Tips. SCAI Quality Improvement Toolkit November 7, 2017. Available form: <https://scai.org/coronary-angiography-intervention-following-tavr-challenges-and-tips>
9. Lederman RJ, Babaliaros VC, Rogers T, Khan JM, Kamioka N, Dvir D, et al. Preventing coronary obstruction during transcatheter aortic valve replacement: from computed tomography to BASILICA. *JACC: Cardiovascular Interventions.* 2019 Jul 8;12(13):1197-216.
10. Lateef N, Khan MS, Deo SV, Yamani N, Riaz H, Virk HU, et al. Meta-analysis comparing outcomes in patients undergoing transcatheter aortic valve implantation with versus without percutaneous coronary intervention. *The American Journal of Cardiology.* 2019 Dec 1;124(11):1757-64.
11. Yudi MB, Sharma SK, Tang GH, Kini A. Coronary angiography and percutaneous coronary intervention after transcatheter aortic valve replacement. *Journal of the American College of Cardiology.* 2018 Mar 27;71(12):1360-78.
12. Brooks MM, Chaitman BR, Nesto RW, Hardison RM, Feit F, Gersh BJ, et al. Clinical and angiographic risk stratification and differential impact on treatment outcomes in the Bypass Angioplasty Revascularization Investigation 2 Diabetes (BARI 2D) trial. *Circulation.* 2012 Oct 23;126(17):2115-24.
13. Kuzo N, Stähli BE, Erhart L, Anwer S, Schindler M, Kebernik J, et al. Outcome of Patients With Severe Aortic Stenosis and Normal Coronary Arteries Undergoing Transcatheter Aortic Valve Implantation. *The American Journal of Cardiology.* 2021 Mar 15;143:89-96.
14. Gersh BJ, Kronmal RA, Schaff HV, Frye RL, Ryan TJ, Mock MB, et al. Comparison of coronary artery bypass surgery and medical therapy in patients 65 years of age or older: a nonrandomized study from the Coronary Artery Surgery Study (CASS) registry. *New England Journal of Medicine.* 1985 Jul 25;313(4):217-24.
15. Passamani E, Davis KB, Gillespie MJ, Killip T, CASS Principal Investigators and Their Associates\*. A randomized trial of coronary artery bypass surgery: survival of patients with a low ejection fraction. *New England Journal of Medicine.* 1985 Jun 27;312(26):1665-71.
16. Xaplanteris P, Fournier S, Pijls NH, Fearon WF, Barbato E, Tonino PA, et al. Five-year outcomes with PCI guided by fractional flow reserve. *New England Journal of Medicine.* 2018 Jul 19;379(3):250-9.
17. Maron DJ, Hochman JS, Reynolds HR, Bangalore S, O'Brien SM, Boden WE, et al. Initial invasive or conservative strategy for stable coronary disease. *New England Journal of Medicine.* 2020 Apr 9;382(15):1395-407.
18. Tonino PA, De Bruyne B, Pijls NH, Siebert U, Ikeno F, vant Veer M, et al. Fractional flow reserve versus angiography for guiding percutaneous coronary intervention. *New England Journal of Medicine.* 2009 Jan 15;360(3):213-24.
19. Pijls NH, van Schaardenburgh P, Manoharan G, Boersma E, Bech JW, van't Veer M, et al. Percutaneous coronary intervention of functionally nonsignificant stenosis: 5-year follow-up of the DEFER Study. *Journal of the American College of Cardiology.* 2007 May 29;49(21):2105-11.
20. Davies JE, Piek JJ. Time for caution interpreting coronary physiology in aortic stenosis?. *EuroIntervention: Journal of EuroPCR in collaboration with the Working Group on Interventional Cardiology of the European Society of Cardiology.* 2018 Jun 1;14(2):132-4.