https://www.scientificarchives.com/journal/archives-of-dentistry

Archives of Dentistry Case Series

Chronic Oral Mucosal Trauma and Oral Cancer: A Series of Cases

Kobkan Thongprasom[1*], Ekarat Phattarataratip[2]

[1]Department of Oral Medicine, Chulalongkorn University, Bangkok 10330, Thailand

[2]Department of Oral Pathology, Chulalongkorn University, Bangkok 10330, Thailand

*Correspondence should be addressed toKobkan Thongprasom; kobkan.t@chula.ac.th

Received date: September 09, 2019, **Accepted date:** October 23, 2019

Abstract

Oral mucosal lesions affect the quality of life of many patients and are an apparent indicator of oral and general health. Red or white lesions in the oral cavity, including asymptomatic ones should never be ignored. Dentist could be the first person performing important roles in the early diagnosis and management of oral lesions. Taking a biopsy should be considered to exclude the possibility of potentially malignant conditions or oral cancers. The aim of these series of cases is to present interesting clinical oral manifestations that demonstrate the relationship between oral hygiene, chronic irritation, dysplasia, and oral squamous cell carcinoma. Oral mucosal changes related to chronic trauma or irritation can greatly impact patient's oral as well as general health.

Keywords: Irritation; Mucosal trauma; Oral cancer; Squamous cell carcinoma

Introduction

The dentist is often the first person who has the opportunity to detect mucosal alterations, such as ulcerations or white and red lesions in the oral cavity. Early diagnosis and proper management can prevent unfavorable outcomes in these patients. Indeed, chronic mucosal trauma resulting from sharp teeth and faulty restorations has been associated with the development of oral cancer [1]. The aim of these series of different ethnic cases is to present and focus on the clinical experiences from various cases in the Oral Medicine clinic at the Faculty of Dentistry, Chulalongkorn University and Bangkok, Thailand. This paper highlights the relationship between long-standing irritation, trauma, poor oral hygiene, old age, and oral cancer. Although not all the risk factors for developing oral squamous cell carcinoma (OSCC) have been determined, it is likely that malignant transformation has a multifactorial etiology [2-4]. Some of the oral manifestations of the cases presented here might explain the possible link to the pathogenesis of OSCC.

Many severe or complicated cases from various parts of Thailand and non-Thai patients were referred to our clinic. Most of the oral lesions were very difficult and challenging to diagnose and treat. Oral white and red lesions or ulcerations need advanced and thorough investigation to make the correct final diagnosis. These lesions affected the quality of life of the patients and their diagnosis was definitely important for the patients' life and general health. In other words, oral tissues are an indicator of general health.

Some of the following interesting cases with oral manifestations may provide evidence concerning the risk factor for developing OSCC.

Cases Presentation

Case I: Chronic irritation from a sharp tooth edge

A 49-year-old Chinese man was referred to our clinic with an ulcerative and keratotic white lesion presented for more than 5 months. The lesion was unresponsive to previous treatment with triamcinolone acetonide 0.1% in orabase. Oral examination at the first visit revealed a keratotic white patch and erythematous area on the gingiva of the right second mandibular premolar and mucobuccal fold extending to the retro molar area that was covered with necrotic tissue on the surface. The anterior part of the lesion had an ulceration with a white patch. Interestingly, the right retro molar area showed a keratotic white lesion and erythematous area that contacted the sharp edge of the distal marginal ridge of the right second mandibular molar (Figure 1). The right and left submandibular lymph nodes appeared normal. However, he did not have any symptoms that might be from his previous treatment with the topical steroid. He had no systemic disease, took no medication, and was a nonsmoker and nondrinker. The histopathological report indicated that the specimen from the area in close contact with the sharp tooth edge showed focal keratosis, chronic mucositis with moderate epithelial dysplasia (Figures 2A and 2B). In this case, the long-term irritation from a sharp tooth edge induced

Figure 1: Sharp edge on the distal marginal ridge of the right second mandibular molar in contact with the lesion. A keratotic white patch and ulcerative area covered with necrotic tissue on the surface of the lesion extended from the gingiva of the right second mandibular premolar and mucobuccalfold to the retromolar area.

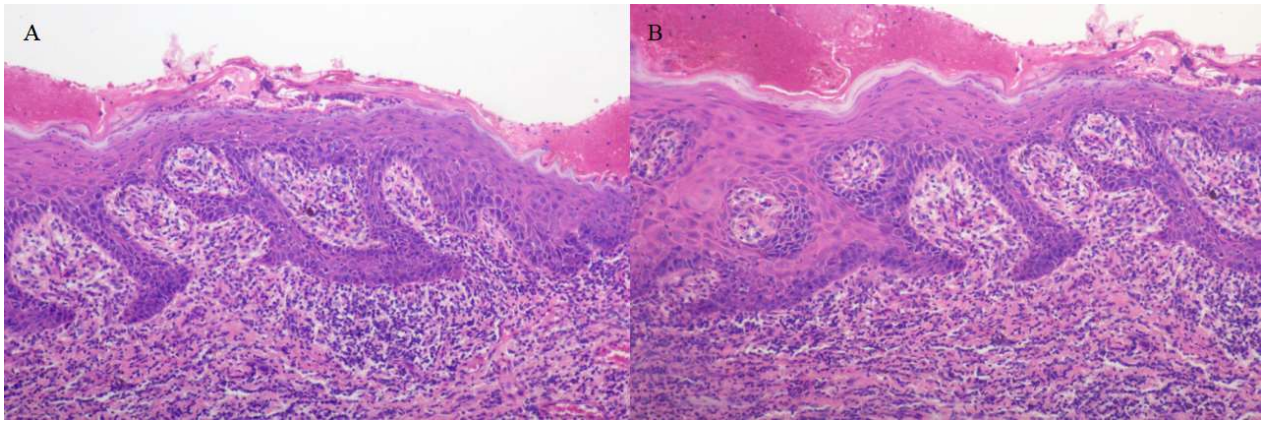

Figure 2A-2B: The specimen is surfaced by parakeratinizing stratified squamous epithelium with irregularly elongated rete ridges. The keratinocytes in the lower half of the epithelium demonstrate suprabasillar mitotic figures, nuclear hyperchromatism and pleomorphism, and some loss of orientation. A dense lymphocytic infiltrate is present directly subjacent to the epithelium. (A, magnification X40; B, magnification X100).

chronic inflammation and subsequently developed into a moderate epithelial dysplasia. This case was referred back to his dentist for oral hygiene control, grinding and polishing the sharp edge of the tooth, and was planned for the appropriate surgical treatment of the lesion.

Case II: Chronic denture irritation

A 50- year-old Thai woman, a business owner, came to the clinic with a complaint of pain on the right lateral surface of the tongue for more than 6 months. She had a history of her removable partial denture clasp arm irritating the right lateral surface of the tongue with ulceration. A previous biopsy by the physician at a private hospital found that the lesion demonstrated mild abnormalities. She had no systemic disease, took no medication, and was a nonsmoker and nondrinker. Her right and left submandibular lymph nodes were normal. Her right lateral tongue revealed a 4 × 1.6 cm erythematous area with multiple ulcerations, and a keratotic white patch at the lower border of the lesion with an ill-defined margin (Figure 3). Histopathological specimen from this area showed the oral mucosa covered with anaplastic squamous epithelium, characterized by nuclear pleomorphism, hyperchromatism, disorientation,

Figure 3: The right lateral tongue revealed a 4 × 1.6 cm erythematous area with multiple ulcerations, and a keratotic white patch at the lower border of the lesion, with an ill-defined margin. This area resulted in a diagnosis of early invasive squamous cell carcinoma.

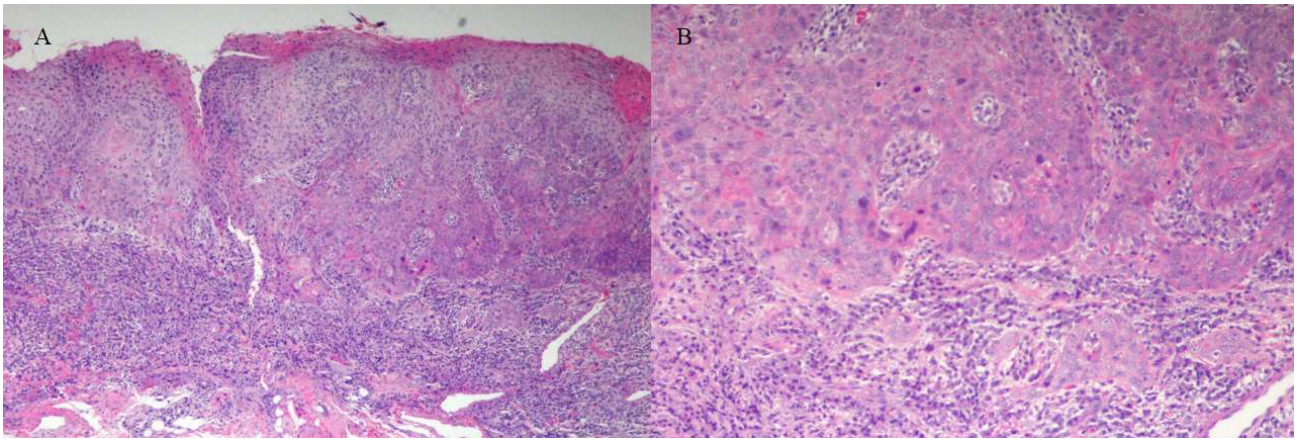

Figure 4A: The specimen consists of acanthotic anaplastic squamous epithelium, characterized by nuclear pleomorphism, hyperchromatism, disorientation, increased mitotic activity and the presence of individual cell keratinization (magnification X40), **4B)** The underlying connective tissue is densely infiltrated by lymphocytes and plasma cells. Invasion of several clusters of atypical squamous cells into the connective tissue is noted. (magnification X100).

increased mitotic activity and the presence of individual cell keratinization as well as epithelial pearls. The underlying connective tissue is densely infiltrated by lymphocytes and plasma cells. Invasion of several clusters of atypical squamous cells into the connective tissue is present (Figures 4A and 4B). Finally, the lesion from the right lateral of tongue was diagnosed as early invasive squamous cell carcinoma.

This case demonstrates that chronic irritation to a long-standing lesion may induce OSCC. She was planned for hemiglossectomy and supraomohyoid neck dissection. This diagnosis definitely changed her life forever.

Case III: Association with dental material

A 66-year-old French man came to our clinic with a painless mass on the left posterior palatal area. He had no systemic diseases, took no medications, and was a nonsmoker and nondrinker. He had many gold crowns and bridges in his oral cavity. A 2 × 1.5 cm mass with irregular surface was noted in close contact with his left maxillary first and second molar gold crowns (Figure 5A). In another area in the oral cavity, keratotic white patches and white striae on the marginal and attached gingiva close to the corroded margin of the right mandibular first and second premolar gold crowns were seen (Figure 5B). Interestingly, lichen planus like-lesions were present on his right and left lower lip (Figure 5C). Unfortunately, this patient had return to his country, therefore a biopsy of the mass lesion could not be performed at that time. However, the most likely diagnosis of the mass on his left gingival palatal area is OSCC. Therefore, an older patient with chronic irritation from a corroded metal crown margin should be carefully followed. In this case, a long standing chronic irritation from corroded metal might induce an oral lichen planus-like lesion and develop to OSCC.

Taken together, the possible relationship of oral trauma and OSCC from our cases is shown in Figure 6.

Figure 5A: The gingival palatal mass with an irregular surface in close contact with the gold crowns, **5B)** white patches and white striae on the marginal and attached gingiva close to the corroded gold crown margins, **5C)** a lichen planus-like lesion can be seen on the right and left lower lip.

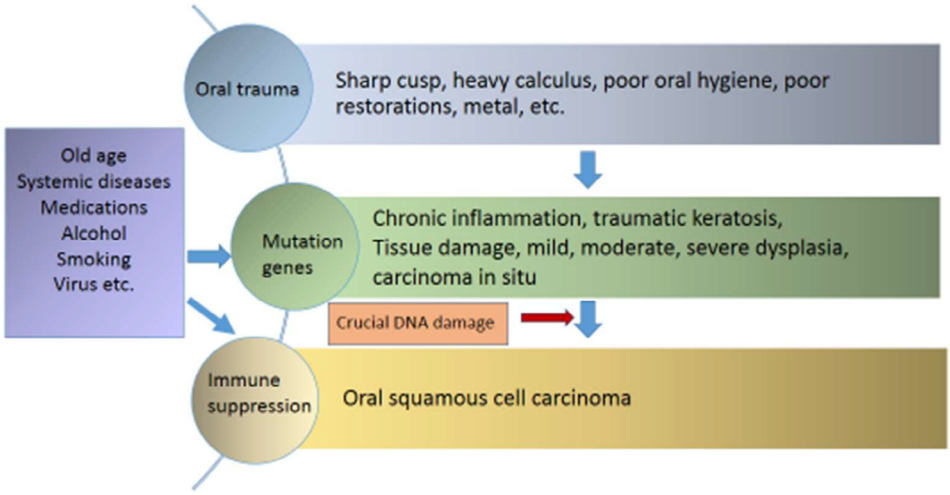

Figure 6: Diagram shows the relationship between oral trauma and oral squamous cell carcinoma.

Discussion

Oral Medicine specialists should provide oral health care promotion and education to every level of the general population. The contribution of poor oral hygiene to the increased risk of head and neck cancer (HNC) development has been documented in previous studies [5,6]. Moreover, the long-term chronic irritation from a sharp tooth edge should be paid attention to and corrected by grinding and polishing it smooth. Broken teeth or poor restorations have to be restored to a good condition. A tooth with a complicated crown fracture that cannot be restored should be extracted as soon as possible. In the case III with corroded crowns, the clinical examination showed lichen planus-like lesion on the lip and a possible OSCC on palatal mucosa. Previous report demonstrated that oral lichen planus-like or lichenoid lesion could transform into an epithelial dysplasia or OSCC [7]. However, the role of metal/gold crown corrosion in developing OSCC is unresolved and needs further investigation involving more cases. Moreover, an oral epithelial dysplasia, often the precursor of OSCC, typically presents itself as a predominantly white, red, or mixed white and red mucosal lesion [8]. White and red lesions with or without symptoms should be carefully evaluated and never ignored. These lesions should have a biopsy taken to exclude the possibility of epithelial dysplasia, carcinoma in situ or invasive squamous cell carcinoma [9]. Previous study showed that lesions demonstrating mild epithelial dysplasia had a malignant transformation rate similar to those with severe dysplasia [10]. Furthermore, a recent review showed strong evidence supporting the association between chronic inflammation and carcinogenesis [11]. The mechanism of developing OSCC following mucosal trauma may involve multiple factors, such as DNA damage, cytokines, human papillomavirus infection, genetic changes, smoking, alcohol, and others [12]. Chronic inflammation can induce persistent tissue damage and changes in types of inflammatory cells. Cytokines present in the tissue microenvironment and inflammation greatly increases the risk of cancer. Moreover, the inflammatory mediators including nuclear factor kappa B, vascular endothelial growth factor, inflammatory cytokines, prostaglandin pathways, p53, reactive oxygen and nitrogen species, and microRNAs are major key players in the pathogenesis of oral cancer [13]. The concept of chronic inflammation results in crucial DNA damage, which further progresses to development of carcinoma has been reported in one study [14]. Therefore, chronic inflammation may influence tumor initiation, progression, invasion, and metastasis via changes in inflammatory-cell populations and cytokine levels in local tissues [15,16]. Oral cavity ulcerations are caused by various etiologic factors including infection, immune dysregulation, trauma, and neoplasms. Neoplastic ulcerated lesions are notorious in the oral cavity for their ability to mimic benign ulcerative lesions, highlighting

the essential nature of biopsy to establish a diagnosis in cases that are not clinically identifiable or do not respond as expected to treatment. Adjunctive tests may be required for final diagnosis of some ulcerated lesions especially autoimmune lesions. Careful clinical, medical history and clinical evaluation may lead to a strong possible clinical diagnosis in many cases, biopsy and/or additional adjunctive testing are necessary to confirm the diagnosis or rule out neoplastic sources [17].

Therefore, eliminating the cause of irritation to the oral mucosa and controlling oral hygiene are mandatory. The early diagnosis of oral lesions, advanced research, and a holistic approach are also important for all patients. Oral medicine specialists and dentists can play important roles and save a patient's life. Education about oral health care and early detection of mucosal lesions are crucial for patients. Further studies in a large population and advanced research are recommended. Taken together, a series of our cases provide clinical evidence of chronic irritation, chronic inflammation and poor oral hygiene as risk factors for oral epithelial dysplasia and OSCC. Proper oral care are therefore vital to patient's general as well as global heath.

Conclusion

Chronic oral mucosal trauma and irritation can affect a patient's oral health, general health, and life. Oral mucosal changes are a clear indicator of oral and general health. Oral medicine specialist and oral pathologist play an important role in the early diagnosis and management of oral lesions.

Acknowledgement

This manuscript is a part of a main lecture of oral presentations entitled " Oral Medicine perspective and global health" for the "3rd International Conference on Global Health (ICGH) that was held in conjunction with the 3rd International Workshop on Dental Research (IWDR) and the 1st International Seminar on Clinical and Research in Dentistry (ISCaRD)", Bali, Indonesia during 14-16 September, 2018.

We thank the Research Unit in Oral Diseases, Chulalongkorn University and Oral Medicine staff for long term support.

We thank Prof. Somporn Swasdison, Oral Pathology Department, Faculty of Dentistry, Chulalongkorn University for histopathological studies. Our patients are also thanked for their kind cooperation.

We also thank Dr. Kevin Tompkins for reviewing and editing this manuscript.

References

1. Singhvi HR, Malik A, Chaturvedi P. The role of chronic mucosal trauma in oral cancer: a review of literature. Indian journal of medical and paediatric oncology: official journal of Indian Society of Medical & Paediatric Oncology. 2017 Jan;38(1):44.

2. Makrilia N, Kollias A, Manolopoulos L, Syrigos K. Cell adhesion molecules: role and clinical significance in cancer. Cancer investigation. 2009 Nov 13;27(10):1023-37.

3. Ouhtit A, Gaur RL, Elmageed ZY, Fernando A, Thouta R, Trappey AK, Abdraboh ME, El-Sayyad HI, Rao P, Raj MG. Towards understanding the mode of action of the multifaceted cell adhesion receptor CD146. Biochimica et Biophysica Acta (BBA)-Reviews on Cancer. 2009 Apr 1;1795(2):130-6.

4. Peng Q, Zhang J, Ye X, Zhou G. Tumor-like microenvironment in oral lichen planus: evidence of malignant transformation?. Expert review of clinical immunology. 2017 Jun 3;13(6):635-43.

5. Kawakita D, Lee YC, Li Q, Chen Y, Chen CJ, Hsu WL, Lou PJ, Zhu C, Pan J, Shen H, Ma H. Impact of oral hygiene on head and neck cancer risk in a Chinese population. Head & neck. 2017 Dec;39(12):2549-57.

6. Hashim D, Sartori S, Brennan P, Curado MP, Wünsch-Filho V, Divaris K, Olshan AF, Zevallos JP, Winn DM, Franceschi S, Castellsagué X. The role of oral hygiene in head and neck cancer: results from International Head and Neck Cancer Epidemiology (INHANCE) consortium. Annals of Oncology. 2016 May 27;27(8):1619-25.

7. Brennan M, Migliorati CA, Lockhart PB, Wray D, Al-Hashimi I, Axéll T, Bruce AJ, Carpenter W, Eisenberg E, Epstein JB, Holmstrup P. Management of oral epithelial dysplasia: a review. Oral Surgery, Oral Medicine, Oral Pathology, Oral Radiology, and Endodontology. 2007 Mar 1;103:S19-e1.

8. Thomson PJ, Goodson ML, Smith DR. Potentially malignant disorders revisited—The lichenoid lesion/proliferative verrucous leukoplakia conundrum. Journal of Oral Pathology & Medicine. 2018 Jul;47(6):557-65.

9. Waal I. Oral lichen planus and oral lichenoid lesions; a critical appraisal with emphasis on the diagnostic aspects.

10. Holmstrup P, Vedtofte P, Reibel J, Stoltze K. Long-term treatment outcome of oral premalignant lesions. Oral oncology. 2006 May 1;42(5):461-74.

11. Mitran MI, Mitran CI, Sarbu MI, Matei C, Nicolae I, Caruntu A, Tocut SM, Popa MI, Caruntu C, Georgescu SR. Mediators of Inflammation–A Potential Source of Biomarkers in Oral Squamous Cell Carcinoma. Journal of immunology research. 2018;2018.

12. Farsi NJ, Rousseau MC, Schlecht N, Castonguay G, Allison P, Nguyen-Tan PF, Souliéres D, Coutlée F, Hier M, Madathil S, Franco EL. Aetiological heterogeneity of head and neck squamous cell carcinomas: the role of human papillomavirus infections, smoking and alcohol. Carcinogenesis. 2017 Sep 28;38(12):1188-95.

13. Patel JB, Shah FD, Joshi GM, Patel PS. Clinical significance of inflammatory mediators in the pathogenesis of oral cancer. Journal of cancer research and therapeutics. 2016 Apr 1;12(2):447.

14. Sagari S, Sanadhya S, Doddamani M, Rajput R. Molecular markers in oral lichen planus: A systematic review. Journal of oral and maxillofacial pathology: JOMFP. 2016 Jan;20(1):115.

15. Suganya G, Bavle RM, Paremala K, Makarla S, Sudhakar M, Reshma V. Survivin expression in oral lichen planus: role in malignant transformation. Journal of oral and maxillofacial pathology: JOMFP. 2016 May;20(2):234.

16. Sun Y, Liu N, Guan X, Wu H, Sun Z, Zeng H. Immunosuppression induced by chronic inflammation and the progression to oral squamous cell carcinoma. Mediators of inflammation. 2016;2016.

17. Fitzpatrick SG, Cohen DM, Clark AN. Ulcerated lesions of the oral mucosa: clinical and histologic review. Head and neck pathology. 2019 Mar 15;13(1):91-102.